

Role for Human Posterior Parietal Cortex in Visual Processing of Aversive Objects in Peripersonal Space

Donna Lloyd, India Morrison and Neil Roberts

JN 95:205-214, 2006. First published Sep 14, 2005; doi:10.1152/jn.00614.2005

You might find this additional information useful...

This article cites 71 articles, 15 of which you can access free at:

<http://jn.physiology.org/cgi/content/full/95/1/205#BIBL>

Updated information and services including high-resolution figures, can be found at:

<http://jn.physiology.org/cgi/content/full/95/1/205>

Additional material and information about *Journal of Neurophysiology* can be found at:

<http://www.the-aps.org/publications/jn>

This information is current as of January 3, 2006 .

Role for Human Posterior Parietal Cortex in Visual Processing of Aversive Objects in Peripersonal Space

Donna Lloyd,^{1,2} India Morrison,³ and Neil Roberts¹

¹Magnetic Resonance and Image Analysis Research Centre, University of Liverpool, Liverpool; ²Pain Research Institute, Clinical Sciences Centre, University Hospital Aintree, Liverpool; and ³Centre for Cognitive Neuroscience, University of Wales Bangor, School of Psychology, Bangor, United Kingdom

Submitted 13 June 2005; accepted in final form 11 September 2005

Lloyd, Donna, India Morrison, and Neil Roberts. A Role for human posterior parietal cortex in visual processing of aversive objects in peripersonal space. *J Neurophysiol* 95: 205–214, 2006. First published September 14, 2005; doi:10.1152/jn.00614.2005. The posterior parietal cortex of both human and non-human primates is known to play a crucial role in the early integration of visual information with somatosensory, proprioceptive and vestibular signals. However, it is not known whether in humans this region is further capable of discriminating if a stimulus poses a threat to the body. In this functional magnetic resonance imaging (fMRI) study, we tested the hypothesis that the posterior parietal cortex of humans is capable of modulating its response to the visual processing of noxious threat representation in the absence of tactile input. During fMRI, participants watched while we “stimulated” a visible rubber hand, placed over their real hand with either a sharp (painful) or a blunt (nonpainful) probe. We found that superior and inferior parietal regions (BA5/7 and BA40) increased their activity in response to observing a painful versus nonpainful stimulus. However, this effect was only evident when the rubber hand was in a spatially congruent (vs. incongruent) position with respect to the participants’ own hand. In addition, areas involved in motivational-affective coding such as mid-cingulate (BA24) and anterior insula also showed such relevance-dependent modulation, whereas premotor areas known to receive multisensory information about limb position did not. We suggest these results reveal a human anatomical-functional homologue to monkey inferior parietal areas that respond to aversive stimuli by producing nocifensive muscle and limb movements.

INTRODUCTION

The brain is organized to support the complex spatial and sensorimotor representations required for interactions with objects in the world, such as navigation and fine manipulation. However, for objects that pose a direct threat to the body, visuospatial and sensorimotor mechanisms may “flag” potentially noxious stimuli relatively early in the visual-processing stream, for example, within structures of the posterior parietal cortex. Such threats are directly relevant to the body and are likely to be most imminent when they occur within the space surrounding a particular body part. In the current study, we investigated whether visual processing of noxious threat-related objects in peripersonal space would activate posterior parietal cortex more than the visual response to a nonthreatening object in the same space.

There is evidence that visuo-tactile receptive fields in monkey inferior parietal and intraparietal cortex are sensitive to

both tactile and visual information about noxious stimuli (Dong et al. 1994). Cells in this region have also been associated with nocifensive movements of aversion (Cooke and Graziano 2003). Apart from these findings, networks classically implicated in the evaluation of the behavioral relevance of aversive stimuli have not included posterior parietal cortex. Rather in the context of pain processing, medial frontal and limbic regions (such as the anterior cingulate and anterior insula cortices) are associated with the evaluation of the motivational and behavioral relevance of the stimulus on the basis of visual or nociceptive information (Botvinick et al. 2005; Jackson et al. 2005; Morrison et al. 2004; Singer et al. 2004), although these studies have largely been concerned with the processing of empathy for pain.

In many situations, the organism must track potential threats in terms of their spatial proximity to particular body parts, and in such circumstances, it would be advantageous for underlying visuomotor representations to be dynamically sensitive to events in the space surrounding that body part. The aim of the current study was to investigate the visual processing of aversive objects in peripersonal space, specifically that surrounding the hand. One possible way of pursuing this would be to stimulate participants’ hand with an aversive (i.e., noxious) stimulus. However, because limb representation involves the multisensory integration of visual, tactile, and proprioceptive cues, this would include the contribution of nociceptive tactile input. An alternative way of isolating the visual component of noxious threat would be to present visual stimuli close to a realistic and aligned artificial limb in peripersonal space that could then be “stimulated” in the absence of actual tactile input. This manipulation has been shown in several studies to result in shifts of the felt location of the limb/and biases in proprioception and or reaching (Armel and Ramachandran 2003; Ehrsson et al. 2004; Farnè et al. 2000; Graziano 1999; Holmes et al. 2005; Pavani et al. 2000; Tastevin 1937; Tsakiris and Haggard 2005; Walton and Spence 2004).

Artificial hands have also recently been used to investigate the neural correlates of subjective limb ownership (Ehrsson et al. 2004). Previous behavioral research has shown that when both an artificial hand and the person’s own hand (which is hidden either beneath or at the side of the person’s own hand) are stroked repeatedly and synchronously by the experimenter, some participants can have the experience that the touch they feel on their own hand is located where they see the rubber

Address for reprint requests and other correspondence: D. Lloyd, School of Psychological Sciences, The University of Manchester, Coupland Bldg., Coupland St., Oxford Rd., Manchester, M13 9PL, UK (E-mail: Donna.Lloyd@manchester.ac.uk).

The costs of publication of this article were defrayed in part by the payment of page charges. The article must therefore be hereby marked “advertisement” in accordance with 18 U.S.C. Section 1734 solely to indicate this fact.

hand being touched. This sensation is often accompanied by a sense of ownership of the rubber hand (Botvinick and Cohen 1998). Using functional magnetic resonance imaging (fMRI), Ehrsson and colleagues provided evidence that the subjective experience of ownership of the rubber hand correlates significantly with premotor cortex activation. In a separate analysis, this activation was observed as an interaction between the synchronicity of the stroking and the anatomical plausibility of the hand's orientation. The impression of ownership of the rubber hand can be substantially reduced or even eliminated by placing the rubber hand in an anatomically implausible position with respect to the participant's real hand, asynchronously touching the real and rubber hand and/or allowing vision of the real hand (see Maravita et al. 2003 for a review).

There is also a multitude of evidence from both animal electrophysiological recordings and human brain imaging studies to suggest that activity in the premotor and posterior parietal cortex (particularly the ventral-intraparietal area; VIP) represents both the *seen* and *felt* position of the hand (for a recent review, see Graziano et al. 2004). Multisensory cells within these regions fire both when the hand is touched or when a visual stimulus is presented near the hand (Rizzolatti et al. 1981) and when a fake hand is seen in place of the real hand (Ehrsson et al. 2004; Graziano 1999). In the monkey, area VIP has direct reciprocal connections with part of the ventral premotor cortex (F4 in PMv), the human homologue of which is the inferior frontal gyrus (BA44) (Rizzolatti et al. 1998), forming a circuit known as the VIP-F4 circuit (Luppino et al. 1999). Further evidence exists of a similar circuit in frontoparietal regions of the human brain responsive to the multisensory representation of limb position (Lloyd et al. 2003).

A study by Armel and Ramachandran (2003) indicates that not only can an artificial hand be incorporated into the subject's own body representation but that autonomic nervous system activity can occur according to the perceived threat of an object in contact with the artificial hand. They measured skin conductance responses (SCRs) while subjects experienced simultaneous and synchronous tactile stimulation of their own and a rubber hand. They found that if the rubber hand was suddenly and unexpectedly "injured" after this simultaneous tactile stimulation, subjects displayed a strong SCR even though they were aware that their real hand was never in danger.

To discover whether a potentially noxious visual stimulus, perceived within peripersonal hand space, would influence hemodynamic responses in the brain, especially within regions implicated in multisensory limb representation, we biased the integration of participants' visual, tactile, and position senses by manipulating the position of the rubber hand over the participants' own hand. Noxious (sharp) or innocuous (blunt) stimulation of the rubber hand was preceded by simultaneous stroking of the real and rubber hand to facilitate participants' perception of the rubber hand as within body-part centered space (although visual capture of limb proprioception can also occur in the absence of synchronous stroking) (see Farnè et al. 2000; Holmes et al. 2005; Pavani et al. 2000; Rorden et al. 1999; Walton and Spence 2004). Specifically, areas previously shown to play a role in coding the space surrounding the hand—such as posterior parietal and premotor cortex—are predicted to distinguish a sharp probe versus a blunt probe striking the rubber hand. Importantly, we expect any such discrimination to depend on the anatomical plausibility of the

false limb's real position influencing the apparent position of the invisible real limb position, responding more when the rubber hand is oriented compatibly with the person's own hand (and thus proprioceptively aligned). A secondary hypothesis is that activity in anterior cingulate and anterior insula, which respond to pain-related visual information and are involved in the motivational-affective aspect of pain processing, will likewise increase for the sharp versus the blunt probe. If these predictions are borne out, the results will provide the first neuroimaging evidence that regions supporting visuo-spatial representations of peripersonal space are capable of discriminating threatening stimuli near the hand.

METHODS

Participants

Twenty-eight participants (9 males, 19 females) aged between 22 and 50 yr (with a mean age of 29 yr) gave fully informed written consent of their willingness to participate in this study, which had local ethics committee approval. Fourteen participants took part in *experiment 1* (rubber hand in a spatially *congruent* position with respect to the participant's own hand), and a further 14 naïve participants took part in *experiment 2* (rubber hand in a spatially *incongruent* position with respect to the participant's own hand). All participants were strongly right-handed as assessed by the Edinburgh Handedness Inventory (Oldfield 1971) and in good health with no past history of psychiatric or neurological disease. Participants had normal or corrected-to-normal (with contact lenses) visual acuity and normal tactile sensation.

Apparatus and materials

A realistic-looking rubber (right) hand was placed on top of the participant's own right hand (*see Fig. 1*). A piece of semi-circular plastic piping was placed in between the rubber hand and the participant's own hand to ensure that touching the rubber hand did not inadvertently tactually stimulate the person's real hand and was covered with a cloth to enable continuity of the perception of the fake hand and arm extending and occupying the position of the partici-

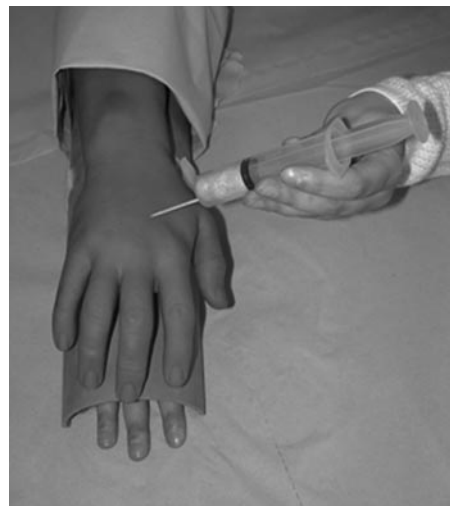

FIG. 1. Photograph of the experimental set-up. Inside the scanner, the rubber hand (representing a right hand) was placed above the participant's real right hand in either an anatomically plausible (*experiment 1*) or implausible (*experiment 2*) position. A piece of semi-circular plastic tubing was placed between the participant's real hand and the rubber hand to prevent secondary contact of the participants hand during stimulation of the rubber hand.

part's real hand and arm. A cotton bud (or Q-tip) and a syringe with a cocktail stick (also called a toothpick) in place of the steel lancet were used as the *innocuous* tactile and painful tactile probes, respectively. The cocktail stick caused a moderately painful pin-prick sensation when applied to the skin (as established on all participants prior to scanning) but does not contain metal and so can be used within the MRI environment. We were able to emulate the experience of a real syringe being applied to the skin by placing it in the plastic holder of a real syringe.

Design and procedure

Prior to scanning, all participants were exposed to the effect of the rubber hand by placing their own hand underneath the plastic tubing with the rubber hand on top (in the congruent position) and a blanket covering their arm to maintain the perception of the rubber hand as an extension of their own arm. We then began simultaneous stroking of the rubber hand and the participant's own hand until they reported such statements to suggest that they could feel as if the rubber hand was their own hand or that they could feel "touch" on the rubber hand. This typically occurred after several seconds. We then stopped the procedure and showed the participants the cotton bud/Q-tip and modified syringe (with the cocktail stick in place instead of the steel lancet) and encouraged them to feel the tactile qualities of these two objects. All participants acknowledged the Q-tip as innocuous and the cocktail stick as moderately painful.

Stimuli were presented within a modified blocked design. At the start of each block, participants experienced 30 s of rest followed by 15 s of simultaneous stroking of the rubber (right) hand and their own right hand in a temporally synchronized and spatially compatible way. Specifically, both the rubber hand and the participant's real hand were stroked by the experimenter (using their index finger) in a unidirectional way on the middle finger of the right hand starting at the finger nail and ending at the proximal interphalangeal joint (mid-way down the finger) at an approximate rate of 1 Hz. In studies where only visual cues of the fake/rubber hand were available (i.e., no simultaneous touch occurred), participants failed to incorporate the fake hand into the body image (Farnè et al. 2000; Pavani et al. 2000). We reasoned that an investigation of the visuo-nociceptive response to threatening objects in peripersonal space would benefit from including this simultaneous touch condition. However, we do not have any formal subjective measures (i.e., via questionnaires) of whether participants experienced the "rubber-hand illusion" per se as this was not the focus of the current study. This manipulation also ensured that in the absence of an explicit task, participants were aware of the rubber hand throughout the 7-min scan. After this time, either the cotton bud or the syringe was administered to the rubber hand for 15 s (the order of which was randomized between subjects), which the participants could see touching the rubber hand but not approaching the rubber hand given the confines of the scanner. Three blocks of each condition (i.e., noxious touch and innocuous touch) were presented. All stimuli were delivered at a steady rate of 1 Hz (practiced outside of the scanner), the duration of the stimulation was timed by a clock on the wall of the scanner, visible to the experimenter but not to the participant inside the scanner. During the prescan setup and during the experiment, participants were instructed to look only at the rubber hand (which they saw indirectly through a mirror positioned in the head coil of the scanner). Although we did not formally track their eye movements during the scan, we are confident participants were looking at the stimuli throughout this novel and stimulating experiment through postscan interviews as to their subjective impression of the effect of having the rubber hand touched with the different stimuli. Their own (right) hand was hidden from view underneath the rubber hand throughout the experiment, and participants were unable to see the experimenter touching their hand as the narrow bore of the magnet restricts the field of view of the participant such that he/she can see the rubber hand (placed over his/her own right hand) and the hands of the

experimenter touching the rubber hand but not the body of the experimenter which is hidden from view at the side of the magnet. In *experiment 1*, the rubber hand was in an anatomically plausible (congruent) position with respect to the participant's real arm (Fig. 1). In *experiment 2*, the position of the rubber hand was rotated 180° such that it faced toward the participant in what was deemed by all to be an anatomically implausible (incongruent) position. This was the optimum position for the rubber hand given the narrow confines of the scanner. Data from *experiment 2* were collected in a different scanning session from that of *experiment 1* and in a different set of participants to eliminate any familiarity or priming effects.

Scanning procedure

MR data were acquired using a 1.5 T Signa LX/Nvi neuro-optimized system (General Electric, Milwaukee, WI). fMRI was performed with a blood oxygenation-level-dependent (BOLD)-sensitive T_2^* -weighted multislice gradient echo EPI sequence (TE = 40 ms, TR = 3 s, flip angle = 90°, FOV = 190 mm, 64 × 64 matrix, in-plane resolution: 3 mm); 135 volumes were collected in a single EPI run. Twenty-four contiguous 5-mm-thick axial slices were prescribed parallel to the AC-PC line and covered the whole brain. For the purpose of anatomical referencing and visualization of brain activation, a high-resolution T_1 -weighted three-dimensional (3D) inversion recovery prepared gradient echo (IRp-GRASS) sequence was acquired (TE = 5.4 ms, TR = 12.3 ms, TI = 450 ms, 1.6-mm slice thickness, FOV = 200 mm, 256 × 192 matrix), with 124 axial slices covering the whole brain (in-plane resolution: 1 mm).

Data analysis was carried out using FEAT5 software (fMRI expert analysis tool, Oxford Centre for Functional Magnetic Resonance Imaging of the Brain, FMRIB, University of Oxford), part of the FMRIB software library [FSL 3.2; www.fmrib.ox.ac.uk/fsl (Smith et al. 2004)]. The following prestatistics processing was applied: motion correction using MCFLIRT (Jenkinson and Smith 2001); spatial smoothing using a Gaussian kernel of FWHM 5 mm; mean-based intensity normalization of all volumes by the same factor; nonlinear high-pass temporal filtering (Gaussian-weighted LSF straight line fitting, with $\sigma = 60$ s). Statistical analysis was carried out using FILM (FMRIB's improved linear model) with local autocorrelation correction of the data (nonlinear spatial smoothing and prewhitening) (Smith and Brady 1997; Woolrich et al. 2001).

For each individual subject, we fitted a linear regression model (general linear model, GLM) to the data (1st level analysis). Four covariates were analyzed separately corresponding to the four experimental conditions: two covariates of interest, viewing the painful stimulus touching the rubber hand (view pain, VP) and viewing the *innocuous* stimulus touching the rubber hand (view neutral, VN) and two covariates of no interest; simultaneous touching of the rubber hand and real hand prior to viewing the painful stimulus (pain rub, PR) and simultaneous touching of the rubber hand and real hand prior to viewing the *innocuous* stimulus (neutral rub, NR). In addition, linear contrasts were also defined within the GLM framework to identify areas in which the activity relating to the painful stimulus touching the rubber hand was greater than the activity to the *innocuous* stimulus touching the rubber hand [i.e., (VP - VN)], both when the hand was in the congruent position [i.e., congruent (VP - VN)] and incongruent position [i.e., incongruent (VP - VN)]. Similarly, contrasts were defined to measure activity in voxels where activity to the *innocuous* stimulus was greater than the painful stimulus [i.e., (VN - VP)], both when the arm was in a spatially congruent and incongruent position. The results from this analysis were contrast estimates for each condition for each of the 28 subjects (contrast images). To accommodate intersubject variability, the contrast images from all subjects were entered into a mixed effects group analysis (a second level analysis also known as random effects) carried out using FEAT5 software (Beckmann et al. 2003; Woolrich et al. 2004). z (Gaussianized T/F) statistic images were thresholded using clusters

TABLE 1. Activation in response to a painful tactile probe touching the rubber hand

Region	MNI Coordinates (x,y,z mm)			Maximum z score	R/L
Congruent Arm Position					
Premotor cortex (BA6)	-54	2	34	5.70	L
Inferior parietal lobe (BA40)	-56	-28	26	5.48	L
Extrastriate cortex (BA18)	-44	-80	-2	5.44	L
Middle temporal gyrus	56	-56	0	5.40	R
Middle frontal gyrus (BA6/8)	50	10	44	4.40	R
Superior frontal gyrus (BA6)	2	12	60	4.18	R
Middle frontal gyrus (BA9)	58	18	32	4.11	R
Inferior frontal gyrus (BA44)	44	18	24	3.99	R
Superior temporal gyrus	48	24	-22	3.81	R
Medial frontal gyrus (BA6)	-4	0	58	3.45	L
Anterior cingulate cortex (BA32)	0	24	38	3.41	—
Incongruent Arm Position					
Extrastriate cortex (BA18)	-42	-74	-6	6.54	L
Medial intraparietal sulcus	-38	-48	52	5.94	L
Parietal operculum (BA40)	60	-20	22	5.93	R
Superior parietal cortex (BA7)	-22	-60	62	5.82	L
Premotor cortex (BA6)	-50	0	30	5.28	L
Middle frontal gyrus (BA6)	-26	-8	56	5.07	L
Superior temporal gyrus	-40	-8	-6	4.90	L
	40	-2	-14	4.85	R
Precentral sulcus	34	-2	50	4.86	R
Inferior frontal gyrus (BA45/46)	48	28	12	4.57	R
	-40	32	4	4.28	L
Anterior cingulate cortex (BA24)	2	-4	34	4.38	R
Posterior cingulate gyrus (BA31)	-14	-32	34	4.17	L
Anterior insula	-36	22	8	3.55	L
Middle frontal gyrus (BA46)	-34	42	16	3.12	L

Activation in response to a painful tactile stimulus touching the rubber hand (representing a right hand) when the hand is in a spatially congruent and incongruent position with respect to the participant's own right hand (activations determined by clusters greater than $z > 2.3$, $P = 0.05$). MNI coordinate and peak z score of the maximum activating voxel in each cluster are shown.

determined by Gaussian random field theory Resel-based correction, which gives the probability of a cluster, given its spatial extent and z threshold, under the null hypothesis and is therefore less conservative than the Bonferroni correction see (Friston et al. 1992; Worsley et al. 1992). Statistic images were thresholded using clusters determined by $z > 2.3$, $P = 0.05$ (corrected for multiple comparisons across the whole brain) and transformed into the stereotaxic space of the Montreal Neurological Institute (MNI) using FLIRT (FMRIB's linear image registration tool) (Jenkinson and Smith 2001).

RESULTS

Analysis of main effects

Viewing a painful tactile probe touching the rubber hand (representing a right hand) with the hand placed in an anatomically plausible (congruent) position (vs. rest) revealed significant activation across a number of parietal and prefrontal regions as predicted. Activation contralateral to the position of the stimulated rubber hand (i.e., covering the person's own right hand) was seen in inferior parietal cortex (BA40), pre-motor cortex (BA6), and inferior frontal gyrus (BA44) as well as extrastriate cortex (BA18) and right superior and middle temporal gyri. Bilateral activation was seen across middle and superior frontal gyri (BA6/8) and anterior cingulate cortex (see Table 1, Fig. 2). Similar sites of activity were observed when viewing a painful tactile stimulus touching the rubber hand with the hand in a spatially incongruent position with respect to

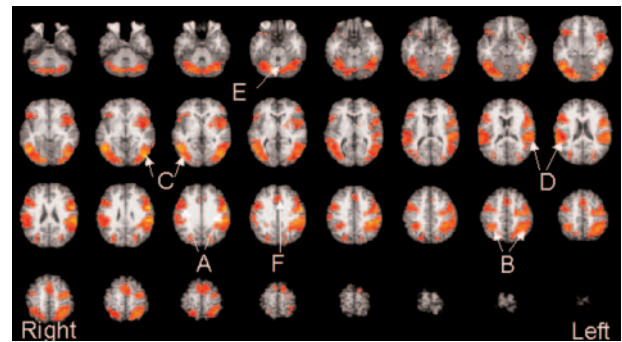


FIG. 2. Activation map illustrating a significantly greater response to viewing the painful tactile probe applied to the rubber hand when the hand was in an anatomically plausible position (with respect to the participants' real hand) vs. rest (no stimulation). Maps were cluster-based thresholded at $z > 2.3$, $P = 0.05$ (corrected for multiple comparisons) and are shown in axial sections across the whole brain starting at the level of the brain stem (moving from left to right across the page in 4-mm slices) in radiological convention (right side of the brain on the left side of the picture). A, pre-motor cortex; B, superior parietal lobe; C, temporal-occipital cortex; D, inferior parietal lobe; E, cerebellum; F, anterior cingulate cortex.

participants' own hands (vs. rest; see Table 1, Fig. 3). Contralateral activity was again observed in pre-motor and middle frontal gyrus (BA6/46), medial intraparietal sulcus and superior parietal lobe (BA7), extrastriate cortex (BA18/19), and anterior insula and posterior cingulate cortex (BA31). Ipsilateral activation was seen within parietal operculum (BA40) and precentral sulcus with bilateral activation occurring within superior temporal and inferior frontal gyri (BA45/46) and anterior cingulate cortex.

Viewing an *innocuous* tactile probe touching the rubber hand with the hand placed in an anatomically plausible (congruent) position (vs. rest) revealed contralateral activation of pre-motor cortex (BA6), superior parietal, and temporal lobes and extrastriate visual cortex. Ipsilateral activation was seen in inferior and middle frontal gyrus (BA44), and bilateral activation in inferior parietal lobe (BA40; see Table 2, Fig. 4). With the rubber hand in a spatially incongruent position with respect to participants' own right hand (vs. rest), significant activation was seen in the contralateral hemisphere in inferior frontal gyrus (BA44/45) and inferior and superior parietal lobes,

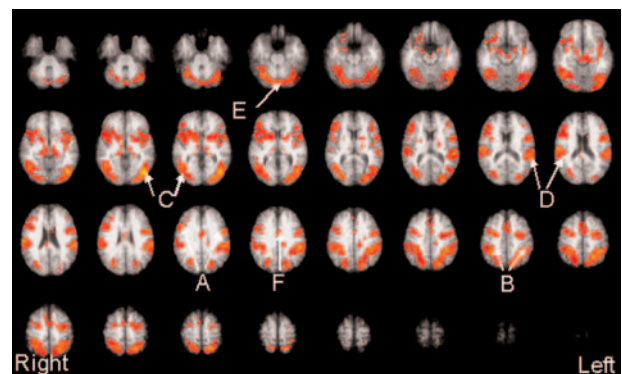


FIG. 3. Activation map illustrating a significantly greater response to viewing the painful tactile probe applied to the rubber hand when the hand was in an anatomically implausible position (with respect to the participants' real hand) vs. rest (no stimulation). Maps were cluster-based thresholded at $z > 2.3$, $P = 0.05$ (corrected for multiple comparisons) and are shown in axial sections across the whole brain starting at the level of the brain stem (moving from left to right across the page in 4-mm slices) in radiological convention (right side of the brain on the left side of the picture).

TABLE 2. Activation in response to an innocuous tactile probe touching the rubber hand

Region	MNI Co-ordinates (x,y,z mm)	Maximum z Score	R/L
Congruent Arm Position			
Extrastriate cortex (BA18)	-46 -76 -2	5.91	L
Inferior parietal lobe (BA40)	-56 -30 24	5.07	L
	68 -22 26	3.71	R
Superior parietal lobe (BA7)	-32 -56 54	5.02	L
Premotor cortex (BA6)	-50 2 36	4.87	L
Middle frontal gyrus (BA6/8/9)	48 8 50	4.66	R
Superior temporal gyrus	-54 8 2	4.17	L
Inferior frontal gyrus (BA44)	58 16 32	3.93	R
Incongruent Arm Position			
Extrastriate cortex (BA18)	-42 -76 -2	6.26	L
Inferior parietal lobe (BA40)	-60 -26 28	5.74	L
Superior parietal lobe (BA7)	-28 -54 50	5.71	L
Premotor cortex (BA6)	-54 2 34	5.13	L
	42 -6 42	3.78	R
Precentral sulcus	-50 0 40	4.90	L
	40 0 42	3.96	R
Sylvian fissure	-54 4 4	4.70	L
	40 -4 -8	3.67	R
Middle frontal gyrus (BA6)	36 -4 48	4.33	R
Inferior frontal gyrus (BA44/45)	-44 40 2	4.22	L
Superior temporal gyrus	-40 -12 -8	4.04	L
Middle frontal gyrus (BA9/10/11)	32 64 -8	3.94	R
Hippocampus	-16 -22 -10	3.89	L
Inferior frontal gyrus (BA47)	26 32 -18	3.83	R
	-44 42 -4	3.41	L
Inferior temporal gyrus	-34 -8 -28	3.67	L
Parahippocampal gyrus	-24 -32 -10	3.61	L

Activation in response to an innocuous tactile stimulus touching the rubber hand (representing a right hand) when the hand is in a spatially congruent and incongruent position with respect to the participants own right hand (activations determined by clusters greater than $z > 2.3$, $P = 0.05$). MNI coordinate and peak z score of the maximum activating voxel in each cluster are shown with the laterality of response.

extrastriate visual cortex (BA18), temporal lobes including the hippocampus and parahippocampal gyrus while premotor cortex activated bilaterally extending into the precentral sulcus, sylvian fissure and inferior frontal gyrus (BA47; see Table 2,

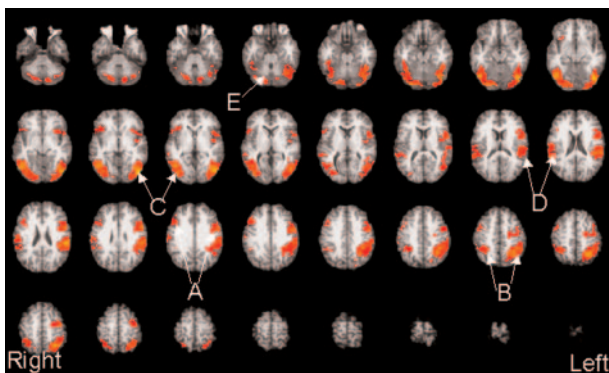


FIG. 4. Activation map illustrating a significantly greater response to viewing the innocuous tactile probe applied to the rubber hand when the hand was in an anatomically plausible position (with respect to the participants' real hand) versus rest (no stimulation). Maps were cluster-based thresholded at $z > 2.3$, $P = 0.05$ (corrected for multiple comparisons) and are shown in axial sections across the whole brain starting at the level of the brain stem (moving from left to right across the page in 4 mm slices) in radiological convention (right side of the brain on the left side of the picture). A = Premotor cortex; B = Superior parietal lobe; C = Temporal-occipital cortex; D = Inferior parietal lobe; E = Cerebellum.

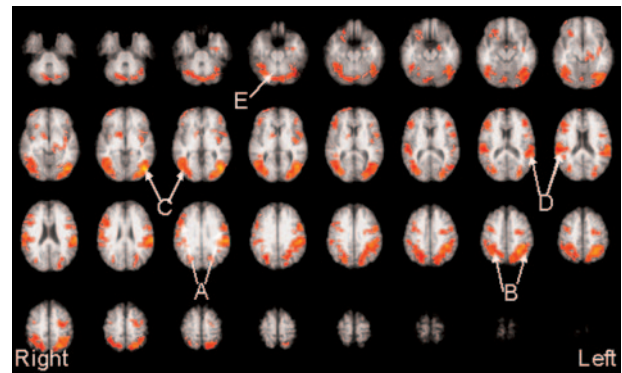


FIG. 5. Activation map illustrating a significantly greater response to viewing the innocuous tactile probe applied to the rubber hand when the hand was in an anatomically implausible position (with respect to the participants' real hand) versus rest (no stimulation). Maps were cluster-based thresholded at $z > 2.3$, $P = 0.05$ (corrected for multiple comparisons) and are shown in axial sections across the whole brain starting at the level of the brain stem (moving from left to right across the page in 4 mm slices) in radiological convention (right side of the brain on the left side of the picture). A = Premotor cortex; B = Superior parietal lobe; C = Temporal-occipital cortex; D = Inferior parietal lobe; E = Cerebellum.

Fig. 5). Ipsilateral activation was seen within middle frontal gyrus (BA6/9/10/11).

Contrast of main effects

A contrast of the main effects revealed those regions which activated significantly more in response to a painful tactile probe touching the rubber hand versus an innocuous tactile probe (and vice versa) either with the rubber hand in a spatially compatible (*experiment 1*) or incompatible (*experiment 2*) position with respect to participants' own right hands. Viewing a painful versus innocuous tactile stimulus touching the rubber hand with the hand in a spatially congruent position [i.e., congruent (VP - VN)] revealed significant contralateral activation of superior and inferior parietal cortices, superior temporal gyrus, and sulcus and fusiform gyrus (BA19). Bilateral activation was observed in the VI lobe of the cerebellum, anterior cingulate cortex (BA24) and medial and superior frontal gyri (BA6) (Table 3; Fig. 6). With the rubber hand in a spatially incongruent position with respect to participants' own hands [i.e., incongruent (VP - VN)] significantly greater activation was seen in response to the painful tactile stimulus versus the innocuous stimulus ipsilaterally in right putamen, superior temporal gyrus and anterior insula (Table 3). At the cluster-based threshold tested ($z > 2.3$, $P = 0.05$), no regions demonstrated significantly more activation to the innocuous tactile stimulus versus the painful stimulus applied to the rubber hand in either a spatially congruent or incongruent position.

DISCUSSION

The major outcome of the current study was that regions of the contralateral posterior parietal cortex (surrounding the intraparietal sulcus) discriminated between painful and non-painful stimulation of a rubber hand in participants' peripersonal hand space. Preferential activation in response to viewing the sharp (painful) stimulus compared with the blunt (non-painful) stimulus contacting the fingers of the rubber hand (in the

TABLE 3. *Regions showing significantly more activation in response to a painful vs. innocuous tactile probe touching the rubber hand*

Region	MNI Coordinates (x,y,z mm)			Maximum z Score	R/L
Congruent Arm Position					
Superior parietal lobe (BA5)	-30	-40	68	3.95	L
Anterior cingulate cortex (BA24)	2	-4	36	3.53	R
	-8	-6	44	3.13	L
Sylvian fissure	-64	-34	20	3.47	L
Cerebellum (VI lobe)	28	-62	-26	3.41	R
	-18	-72	-22	3.48	L
Medial frontal gyrus (BA6)	0	-2	64	3.43	—
	-4	-14	70	2.94	L
Superior parietal lobe (BA7)	-12	-46	62	3.38	L
Superior temporal gyrus	-48	-30	12	3.27	L
Superior frontal gyrus (BA6)	-8	4	72	3.05	L
	8	-2	72	2.96	R
Fusiform gyrus (BA19)	-34	-68	-12	3.00	L
Superior temporal gyrus	-44	-40	12	2.78	L
Inferior parietal lobe (BA40)	-60	-36	38	2.54	L
Incongruent Arm Position					
Anterior Insula	34	12	2	5.03	R
Putamen	26	10	2	3.41	R
Superior temporal gyrus	48	2	0	3.14	R

Areas showing significantly greater activation in response to a painful tactile stimulus touching the rubber hand (vs. an innocuous stimulus) both with the hand in a spatially congruent and incongruent position with respect to the participants own hand (activations determined by clusters greater than $z > 2.3$, $P = 0.05$). MNI coordinate and peak Z score of the maximum activating voxel in each cluster are shown with the laterality of response.

absence of actual tactile input to the real hand and with the rubber hand in an anatomically plausible position) was seen in superior parietal (BA5/7) and inferior parietal (BA40) cortices. Other areas showing similar BOLD signal modulation included mid-cingulate and superior-medial frontal lobe, the cerebellum, and the fusiform and superior temporal gyri. On the basis of these results, we propose that the response of the posterior parietal cortex points to its role in the visuospatial encoding of noxious threats, operating alongside other motivational, proprioceptive, and movement-related areas in representing motivationally significant aversive events.

Posterior parietal cortex and noxious threat representation

A primary function of posterior parietal cortex is the integration of visuospatial and somatosensory information to shape an appropriate motor response (for a recent account, see Grefkes and Fink 2005). In the monkey, the inferior and superior posterior parietal areas chiefly receive visual inputs from striate cortex but are also the first regions along the dorsal visual stream to integrate these retinally derived signals with other sensory signals (such as somatosensory and proprioceptive afferents) to form a higher-order representation of visual space (Driver and Mattingley 1998). Rizzolatti (Rizzolatti and Matelli 2003) has proposed a separation of the dorsal-stream parietal areas into two distinct “sub-streams,” ventral and dorsal. In particular, the ventral part of the dorsal stream is comprised of inferior parietal regions (PF and PG) and supports visual representations of space for the purposes of organizing action. These regions have also been associated with action intention (Andersen and Buneo 2002) and are exten-

sively connected with frontal premotor areas (Rizzolatti and Matelli 2003; Shipp et al. 1998).

The inferior parietal area observed in our study is in the region of the human homologue of monkey areas PF and PG, which play just such a role in the organization of action with respect to objects in space. Although posterior parietal processing is mainly insulated from semantic information about objects from the ventral visual stream, studies of human-neglect patients have indicated that inferior parietal cortex is itself involved in implicit visual awareness of objects in the context of movement planning (Marshall and Halligan 1988; Rizzolatti and Berti 1990). We therefore suggest a role for the inferior parietal area in the motivational response to threatening stimuli visually encoded in peripersonal space.

Further to its role in integrating visual responses to objects in peripersonal space, in humans, posterior parietal damage can alter pain sensation, sometimes resulting in hypoalgesia and asymbolia for pain (Berthier et al. 1988; Greenspan and Winfield 1992). Microstimulation in an epilepsy patient has been observed to evoke a painful somatosensory aura (Salanova et al. 1995). So far, however, very little is known about the role of the human posterior parietal cortex in processing visual information about pain, yet there is evidence that visuo-tactile receptive fields in monkey inferior parietal and intraparietal cortex are sensitive to both tactile and visual information about noxious stimuli (Dong et al., 1994). In these areas, the visual receptive field is bound to the space surrounding the tactile receptive field, e.g., the hand or face. In the macaque, one study showed that a proportion of cells in inferior parietal area PF fired both when skin on the face was stimulated with noxious heat and when the monkey viewed a threatening stimulus coming toward or hovering near that part of the skin (Dong et al. 1996). Furthermore, the responses of these cells closely matched the behavioral response curves for a tolerance-escape task the monkeys performed. Similarly, cells in nearby ventral intraparietal area (VIP) have also shown specifically nocifensive properties. Microstimulation here has produced eye, lip, and arm movements comparable to those elicited by an aversive airpuff into the eyes (Cooke and Graziano 2003).

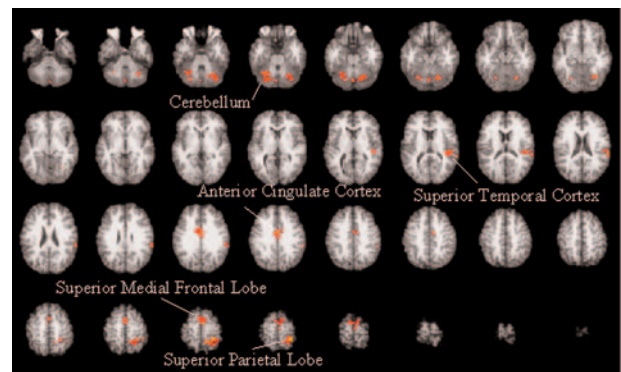


FIG. 6. Activation map illustrating a significantly greater response to viewing the painful tactile probe applied to the rubber hand when the hand was in an anatomically plausible position (with respect to the participants' real hand) versus the innocuous tactile probe. Maps were cluster-based thresholded at $Z > 2.3$, $P = 0.05$ (corrected for multiple comparisons) and are shown in axial sections across the whole brain starting at the level of the brain stem (moving from left to right across the page in 4 mm slices) in radiological convention (right side of the brain on the left side of the picture).

Possible visuospatial network for motivational relevance

Here we postulate a possible network for the visuospatial encoding of aversive stimuli. The overarching feature of this network is the encoding of visuospatial information in body-part-centered terms for the ultimate purpose of organizing effective action away from the aversive stimulus. The main functional components of this network are body-part-centered encoding of the space surrounding the hand (in our study, the interpretation of “rubber-hand space” as peripersonal hand space), discriminating the motivational relevance of objects in that space (here, whether the probe was noxious or innocuous), and elaborating the motivational-affective sensorimotor representation of the stimulus in terms of appropriate motor responses.

The object in hand space becomes incorporated into the body schema in the sense that the space surrounding the rubber hand is interpreted as that surrounding the real hand. Under normal circumstances, proprioceptive and tactile input from one's real hand would be in register with the visual information about hand position. In this study, we highlighted the visual, not the tactile, component of the representation of hand space by using a rubber hand that occluded the real hand from view. Because vision often dominates touch in cases of multisensory spatial conflict, it is very likely that objects within this surrogate hand space were interpreted by posterior parietal visual areas as being near the real, proprioceptively sensed hand and thus processed in hand-centered terms. Studies in monkeys and humans have shown this peripersonal space around the hand to be dynamic, extending a virtual body envelope around not only the hand but also non-body objects within it, such as tools (Maravita et al. 2001, 2002; for an alternative view, see Holmes et al. 2004), artificial limbs (Botvinick et al. 1998; Graziano et al. 2000; Pavani et al. 2000), and even the adjacent tabletop (Armel et al. 2003).

An element of this body-schema incorporation depends merely on there being an object within the peripersonal hand space. The main effects (Tables 1 and 2) revealed a contralateral parietal opercular cluster (BA40) and an ipsilateral superior parietal area (BA7) that did not differentiate between a hand that was oriented in an anatomically plausible way and one that was rotated 180°. However, other pain-preferring posterior parietal areas were sensitive to the orientation of the hand. This is consistent with monkey studies in which individual neurons' responses to a plausible artificial limb decreased when the anatomical plausibility was violated or when the object did not resemble a hand (Graziano 1999; Graziano et al. 2000). The parietal opercular area also showed a significant response to viewing the nonpainful tactile stimulus, but both posterior parietal areas showed significantly higher responses to the painful as compared with the nonpainful stimulus (Table 3).

Another such posture-sensitive activation was seen in the cerebellum, which is, among other things, heavily implicated in position sense as well as in nociception (for a recent review, see Saab and Willis 2003). Major afferents to the cerebellum come from inferior parietal cortex and cingulate gyrus. It also receives visual projections from two ventral-stream areas that differentiated between painful and nonpainful stimuli: extrastriate area 19, and the suprasylvian fissure (Saab and Willis 2003). According to Blakemore and colleagues (2001), the cerebellum uses a forward model to compare the predicted

consequences of an action to the actual result of an action and updates the prediction accordingly. To do this they suggest that activity in the cerebellum depends on the sensory-specific consequences of movement and signaling the sensory discrepancy between predicted and actual sensory feedback. For example, the cerebellum may be involved in signaling the discrepancy of seeing a painful probe touch the rubber hand, which the participant has incorporated into his/her own body representation, but not feeling any painful tactile sensation resulting from the probe touching the skin.

Relationship with classical motivational-affective networks

Beyond its initial visuospatial representation, the relevance of the object in hand space is evaluated in motivational terms. Our results suggest that posterior parietal regions are capable of discriminating between painful and nonpainful stimuli. Other areas conventionally associated with the motivational and affective evaluation of aversive stimuli were also preferentially active to the painful stimulus. It is interesting that two of these, the putamen and right anterior insula, preferred the implausible orientation. The putamen and anterior insula have often been reported in neuroimaging studies of pain (Bingel et al. 2004; Bowsher et al. 2004; Brooks et al. 2002, 2005), and the insula may have a unique role in empathy for pain (Decety and Jackson 2004; Morrison et al. 2004; Singer et al. 2004). If the representation of aversive events in the anterior insula and putamen is not strictly bound to visuospatial and -tactile coherence, it may not be “tricked” by seeing the rubber hand receiving noxious stimulation in this context.

Alongside the posterior parietal areas, the anterior cingulate activations revealed by the contrast between painful and nonpainful stimuli (Fig. 6) are of particular interest. The anterior cingulate cortex focus seen in this study is well-positioned to correspond to cingulate motor areas (CMAs) as determined by human functional and cytoarchitectonic studies (Vogt and Sikes 2000; Vogt et al. 2003). The CMAs receive dense projections from inferior parietal lobe (Isomura and Takada 2004; Matelli et al. 1991; Strick et al. 1998). The nociceptive function of these mid-cingulate areas is well established (Sewards and Swards 2002; Vogt and Sikes 2000). The focus seen in this study was in a posterior mid-cingulate region that is thought to play a role in short-latency sensorimotor orienting to painful stimuli, perhaps using spatial information from its parietal inputs (Vogt et al. 2003). In the monkey, CMAs send fibers to premotor and primary motor cortices as well as having direct projections to dorsal horn motoneurons in the spinal cord (Isomura and Takada 2004; Matelli et al. 1991; Paus 2001). The motor areas show moderate somatotopic organization for trunk and distal and proximal limbs, and representations of cutaneous as well as skeletal muscles have been observed here in the macaque (Akazawa et al., 2000).

CMAs in posterior mid-cingulate are considerably more interconnected with rostral mid-cingulate regions, which also fall within the cluster significantly activated for the painful stimulus. Whereas CMAs have predominantly premotor properties, these nearby mid-cingulate areas are also associated with the motivational-affective dimension of pain processing (Price 2000; Rainville et al. 1997; Swards and Swards 2002) and response selection (Hoshi et al. 2005; Isomura et al. 2004). In that context, their role is tied to the ability to link events with

outcomes, allowing the prediction and avoidance of noxious stimuli. Both CMAs and adjacent rostral mid-cingulate are characterized by dense fast excitatory (*N*-methyl-D-aspartate) and inhibitory (AMPA) receptor types (Bozkurt et al. 2005). It is therefore possible that the activity observed in the BOLD signal change in this region is due to the facilitation of an appropriate response to a threat in hand space, but by the same token, it may reflect inhibition related to sensorimotor response potentiation.

In summary, we propose that posterior parietal areas play a role in immediate, reactive nocifensive responses. These responses are tied to specific effectors and are coded in an egocentric spatial reference frame. Via direct cortical connections they provide initial information to cingulate motor and frontal premotor areas about the relevance of the stimulus. The mid-cingulate in particular may be involved in elaborating the representation of stimulus valence and is involved in more flexible motor response selection, learning, and regulation. Both mid-cingulate and prefrontal regions use contextual information and past experience to produce appropriate responses (Hadland et al. 2003; MacDonald et al. 2000; Matsumoto et al. 2003). The representation of pain in these areas is more flexible in the sense that they support a “generative” (Haggard 2001) representation of the noxious stimulus; that is, they incorporate factors such as current task constraints, motivational values, and past experience to produce behavioral outcomes that are not predictable from the nature of the stimulus alone. This representation is predictive, labile, and probably less immediately dependent on specific effectors or spatial information (Mesulam 1999).

Role of premotor cortex

Contrary to our initial hypothesis premotor cortex did not significantly change its response to viewing a painful tactile stimulus touching the rubber hand despite the fact that this region was activated consistently in all conditions (see Tables 1 and 2 of main effects). Posterior parietal and frontal premotor areas of the primate brain share dense inter-projections forming well-studied functional circuits for the planning and control of action (e.g., Rizzolatti and Luppino 2001). Despite several methodological differences, there is good correspondence between the sites of premotor cortex activation in the current study and those found by Ehrsson et al. (2004). Ehrsson and colleagues used fMRI to explore the neural correlates of the rubber-hand illusion with respect to the subjective sensation of limb ownership. The illusion was associated with activation along the left inferior precentral sulcus (BA44/6), the posterior bank of which corresponds to ventral premotor area 6 and the anterior bank to the posterior part of area 44. When the rubber hand was both plausibly oriented and synchronously stroked, the response in premotor cortex was superadditive, and correlated positively with subjective ratings about the strength of the illusion.

This region is well suited to the multisensory representation of one's own body as it is anatomically connected to visual and somatosensory areas in the posterior parietal cortex and to frontal motor areas (Rizzolatti et al. 1998). Cells in the parietal and premotor cortex have been shown to represent both the seen and felt position of the hand in both humans and non-human primates, discharging when the hand is touched or

when a visual stimulus is presented near the hand (Lloyd et al. 2003; for a recent review, see Graziano et al. 2004). However, despite its sensitivity to multisensory proprioceptive and tactile input, we did not see any evidence for a differential response to painful and nonpainful tactile probes touching the rubber hand using fMRI. However, the population response of cells in this region may have been too small to detect with fMRI, and it would be premature to say that the premotor cortex does not directly encode the biological relevance of stimuli touching or approaching the hand.

Conclusions

This study provides the first neuroimaging evidence of a role for human posterior parietal cortex in the visuospatial coding of the motivational relevance of events in hand space. We observed a significant increase in activation in this region in response to viewing painful (vs. innocuous) stimulation of the rubber hand (when in an anatomically plausible position) in the absence of tactile stimulation of the real hand. This is consistent with primate research that has shown similar preferential spatial encoding of noxious stimuli in posterior parietal areas, suggesting that homologous regions in the human brain may share similar functions in this regard. In our study, however, premotor areas associated with the subjective feeling of limb ownership did not discriminate between painful and nonpainful stimuli. These results provide compelling hints of an integrative network supporting visuospatial and sensorimotor aspects of aversive events in the primate brain that future research can explore.

ACKNOWLEDGMENTS

The authors thank N. Holmes, J. Parkinson, and G. di Pellegrino for reading an earlier version of this manuscript and the staff and radiographers at the Walton Centre for Neurology and Neurosurgery, Liverpool, UK.

REFERENCES

- Akazawa T, Tokuno H, Nambu A, Hamada I, Ito Y, Ikeuchi Y, Imanishi M, Hasegawa N, Hatanaka N, and Takada M. A cortical motor region that represents the cutaneous back muscles in the macaque monkey. *Neurosci Lett* 282: 125–128, 2000.
- Andersen RA and Buneo CA. Intentional maps in posterior parietal cortex. *Annu Rev Neurosci* 25: 189–220, 2002.
- Armstrong KC and Ramachandran VS. Projecting sensations to external objects: evidence from skin conductance response. *Proc R Soc Lond B Biol Sci* 270: 1499–1506, 2003.
- Beckmann CF, Jenkinson M, and Smith SM. General multilevel linear modeling for group analysis in FMRI. *Neuroimage* 20: 1052–1063, 2003.
- Berthier M, Starkstein S, and Leiguarda R. Asymbolia for pain: a sensory-limbic disconnection syndrome. *Ann Neurol* 24: 41–49, 1988.
- Bingel U, Glascher J, Weiller C, and Buchel C. Somatotopic representation of nociceptive information in the putamen: an event-related fMRI study. *Cereb Cortex* 14: 1340–1345, 2004.
- Blakemore SJ, Frith CD, and Wolpert DM. The cerebellum is involved in predicting the sensory consequences of action. *Neuroreport* 12: 1879–1884, 2001.
- Botvinick M and Cohen J. Rubber hands “feel” touch that eyes see. *Nature* 391: 756, 1998.
- Botvinick M, Jha AP, Bylsma LM, Fabian SA, Solomon PE, and Prkachin KM. Viewing facial expressions of pain engages cortical areas involved in the direct experience of pain. *Neuroimage* 25: 312–319, 2005.
- Bowsher D, Brooks J, and Enevoldson P. Central representation of somatic sensations in the parietal operculum (SII) and insula. *Eur Neurol* 52: 211–225, 2004.
- Bozkurt A, Zilles K, Schleicher A, Kamper L, Arigita ES, Uylings HB, and Kotter R. Distributions of transmitter receptors in the macaque cingulate cortex. *Neuroimage* 25: 219–229, 2005.

- Brooks JC, Nurmikko TJ, Bimson WE, Singh KD, and Roberts N.** fMRI of thermal pain: effects of stimulus laterality and attention. *Neuroimage* 15: 293–301, 2002.
- Brooks JC, Zambreanu L, Godinez A, Craig AD, and Tracey I.** Somatotopic organisation of the human insula to painful heat studied with high resolution functional imaging. *Neuroimage* 27: 201–209, 2005.
- Cooke DF and Graziano MS.** Defensive movements evoked by air puff in monkeys. *J Neurophysiol* 90: 3317–3329, 2003.
- Decety J and Jackson PL.** The functional architecture of human empathy. *Behav Cogn Neurosci Rev* 3: 71–100, 2004.
- Dong WK, Chudler EH, Sugiyama K, Roberts VJ, and Hayashi T.** Somatosensory, multisensory, and task-related neurons in cortical area 7b (PF) of unanesthetized monkeys. *J Neurophysiol* 72: 542–564, 1994.
- Dong WK, Hayashi T, Roberts VJ, Fusco BM, and Chudler EH.** Behavioural outcome of posterior parietal cortex injury in the monkey. *Pain* 64: 579–587, 1996.
- Driver J and Mattingley JB.** Parietal neglect and visual awareness. *Nat Neurosci* 1: 17–22, 1998.
- Ehrsson HH, Spence C, and Passingham RE.** That's my hand! Activity in premotor cortex reflects feeling of ownership of a limb. *Science* 305: 875–877, 2004.
- Farnè A, Pavani F, Meneghello F, and Ladavas E.** Left tactile extinction following visual stimulation of a rubber hand. *Brain* 123: 2350–2360, 2000.
- Friston K, Worsley K, Frackowiak RJ, Mazziotta JC, and Evans AC.** Assessing the significance of focal activations using their spatial extent. *Hum Brain Mapp* 1: 214–220, 1992.
- Graziano MS.** Where is my arm? The relative role of vision and proprioception in the neuronal representation of limb position. *Proc Natl Acad Sci USA* 96: 10418–10421, 1999.
- Graziano MS, Cooke DF, and Taylor CS.** Coding the location of the arm by sight. *Science* 290: 1782–1786, 2000.
- Graziano MSA, Gross CG, Taylor CSR, and Moore, T.** A system of multimodal areas in the primate brain. In: *Crossmodal Space and Crossmodal Attention*, edited by Spence C and Driver J. Oxford, UK: Oxford Univ. Press, 2004, p. 51–67.
- Greenspan JD and Winfield JA.** Reversible pain and tactile deficits associated with a cerebral tumor compressing the posterior insula and parietal operculum. *Pain* 50: 29–39, 1992.
- Grefkes C and Fink GR.** The functional organization of the intraparietal sulcus in humans and monkeys. *J Anat* 207: 3–17, 2005.
- Hadland KA, Rushworth MF, Gaffan D, and Passingham RE.** The anterior cingulate and reward-guided selection of actions. *J Neurophysiol* 89: 1161–1164, 2003.
- Haggard P.** The psychology of action. *Br J Psychol* 92: 113–128, 2001.
- Holmes NP, Calvert GA, and Spence C.** Extending or projecting peripersonal space with tools? Multisensory interactions highlight only the distal and proximal ends of tools. *Neurosci Lett* 372: 62–67, 2004.
- Holmes NP, Snijders HJ, and Spence C.** Reaching with alien limbs: Visual exposure to prosthetic hands in a mirror biases proprioception without accompanying illusions of ownership. *Percept Psychophys* In press.
- Hoshi E, Sawamura H, and Tanji J.** Neurons in the rostral cingulate motor area monitor multiple phases of visuomotor behavior with modest parametric selectivity. *J Neurophysiol* 94: 640–656, 2005.
- Isomura Y and Takada M.** Neural mechanisms of versatile functions in primate anterior cingulate cortex. *Rev Neurosci* 15: 279–291, 2004.
- Jackson PL, Meltzoff AN, and Decety J.** How do we perceive the pain of others? A window into the neural processes involved in empathy. *Neuroimage* 24: 771–779, 2005.
- Jenkinson M and Smith S.** A global optimisation method for robust affine registration of brain images. *Med Image Anal* 5: 143–156, 2001.
- Lloyd DM, Shore DI, Spence C, and Calvert GA.** Multisensory representation of limb position in human premotor cortex. *Nat Neurosci* 6: 17–18, 2003.
- Luppino G, Murata A, Govoni P, and Matelli M.** Largely segregated parietofrontal connections linking rostral intraparietal cortex (areas AIP and VIP) and the ventral premotor cortex (areas F5 and F4). *Exp Brain Res* 128: 181–187, 1999.
- MacDonald AW III, Cohen JD, Stenger VA, and Carter CS.** Dissociating the role of the dorsolateral prefrontal and anterior cingulate cortex in cognitive control. *Science* 288: 1835–1838, 2000.
- Maravita A, Husain M, Clarke K, and Driver J.** Reaching with a tool extends visual-tactile interactions into far space: evidence from cross-modal extinction. *Neuropsychologia* 39: 580–585, 2001.
- Maravita A, Spence C, and Driver J.** Multisensory integration and the body schema: close to hand and within reach. *Curr Biol* 13: R531–R539, 2003.
- Maravita A, Spence C, Kennett S, and Driver J.** Tool-use changes multimodal spatial interactions between vision and touch in normal humans. *Cognition* 83: B25–B34, 2002.
- Marshall JC and Halligan PW.** Blindsight and insight in visuo-spatial neglect. *Nature* 336: 766–767, 1988.
- Matelli M, Luppino G, and Rizzolatti G.** Architecture of superior and mesial area 6 and the adjacent cingulate cortex in the macaque monkey. *J Comp Neurol* 311: 445–462, 1991.
- Matsumoto K, Suzuki W, and Tanaka K.** Neuronal correlates of goal-based motor selection in the prefrontal cortex. *Science* 301: 229–232, 2003.
- Mesulam MM.** Spatial attention and neglect: parietal, frontal and cingulate contributions to the mental representation and attentional targeting of salient extrapersonal events. *Philos Trans R Soc Lond B Biol Sci* 354: 1325–1346, 1999.
- Morrison I, Lloyd D, di Pellegrino G, and Roberts N.** Vicarious responses to pain in anterior cingulate cortex: Is empathy a multisensory issue? *Cogn Affective Behav Neurosci* 4: 270–278, 2004.
- Oldfield RC.** The assessment and analysis of handedness: the Edinburgh inventory. *Neuropsychologia* 9: 97–113, 1971.
- Paus T.** Primate anterior cingulate cortex: where motor control, drive and cognition interface. *Nat Rev Neurosci* 2: 417–424, 2001.
- Pavani F, Spence C, and Driver J.** Visual capture of touch: out-of-the-body experiences with rubber gloves. *Psychol Sci* 11: 353–359, 2000.
- Price DD.** Psychological and neural mechanisms of the affective dimension of pain. *Science* 288: 1769–1772, 2000.
- Rainville P, Duncan GH, Price DD, Carrier B, and Bushnell MC.** Pain affect encoded in human anterior cingulate but not somatosensory cortex. *Science* 277: 968–971, 1997.
- Rizzolatti G and Berti A.** Neglect as a neural representation deficit. *Rev Neurol* 146: 626–634, 1990.
- Rizzolatti G, Fogassi L, and Gallese V.** Motor and cognitive functions of the ventral premotor cortex. *Curr Opin Neurobiol* 12: 149–154, 2002.
- Rizzolatti G and Luppino G.** The cortical motor system. *Neuron* 31: 889–901, 2001.
- Rizzolatti G, Luppino G, and Matelli M.** The organization of the cortical motor system: new concepts. *Electroencephalogr Clin Neurophysiol* 106: 283–296, 1998.
- Rizzolatti G and Matelli M.** Two different streams form the dorsal visual system: anatomy and functions. *Exp Brain Res* 153: 146–157, 2003.
- Rizzolatti G, Scandolara C, Matelli M, and Gentilucci M.** Afferent properties of pericruciate neurons in macaque monkeys. II. Visual responses. *Behav Brain Res* 2: 147–163, 1981.
- Rorden C, Heutink J, Greenfield E, and Robertson IH.** When a rubber hand “feels” what the real hand cannot. *Neuroreport* 10: 135–138, 1999.
- Saab CY and Willis WD.** The cerebellum: organization, functions and its role in nociception. *Brain Res Brain Res Rev* 42: 85–95, 2003.
- Salanova V, Andermann F, Rasmussen T, Olivier A, and Quesney LF.** Parietal lobe epilepsy. Clinical manifestations and outcome in 82 patients treated surgically between 1929 and 1988. *Brain* 118: 607–627, 1995.
- Sewards TV and Sewards MA.** The medial pain system: neural representations of the motivational aspect of pain. *Brain Res Bull* 59: 163–180, 2002.
- Shipp S, Blanton M, and Zeki S.** A visuo-somatomotor pathway through superior parietal cortex in the macaque monkey: cortical connections of areas V6 and V6A. *Eur J Neurosci* 10: 3171–3193, 1998.
- Singer T, Seymour B, O'Doherty J, Kaube H, Dolan RJ, and Frith CD.** Empathy for pain involves the affective but not sensory components of pain. *Science* 303: 1157–1162, 2004.
- Smith S and Brady M.** SUSAN - a new approach to low level image processing. *Intl J Comput Vision* 23: 45–78, 1997.
- Smith SM, Jenkinson M, Woolrich MW, Beckmann CF, Behrens TE, Johansen-Berg, H, Bannister PR, De Luca M, Drobnjak I, Fritney DE, Niazky RK, Saunders J, Viceri J, Zang Y, De Stefano M, Brady JM, and Matthews PM.** Advances in functional and structural MR image analysis and implementation as FSL. *Neuroimage* 23 Suppl 1: S208–S219, 2004.
- Strick PL, Dum RP, and Picard N.** Motor areas on the medial wall of the hemisphere. *Novartis Found Symp* 218: 64–75, 1998.
- Tastevin J.** En partant de l'expérience d'Aristotele. *L'Encephale* 1: 57–84, 1937.
- Tsakiris M and Haggard P.** The rubber hand illusion revisited: visuotactile integration and self-attribution. *J Exp Psychol Hum Percept Perform* 31: 80–91, 2005.

- Vogt BA, Berger GR, and Derbyshire SW.** Structural and functional dichotomy of human midcingulate cortex. *Eur J Neurosci* 18: 3134–3144, 2003.
- Vogt BA and Sikes RW.** The medial pain system, cingulate cortex, and parallel processing of nociceptive information. *Prog Brain Res* 122: 223–235, 2000.
- Walton M and Spence C.** Cross-modal congruency and visual capture in a visual elevation-discrimination task. *Exp Brain Res* 154: 113–120, 2004.
- Woolrich MW, Behrens TE, Beckmann CF, Jenkinson M, and Smith SM.** Multilevel linear modelling for FMRI group analysis using Bayesian inference. *Neuroimage* 21: 1732–1747, 2004.
- Woolrich MW, Ripley BD, Brady M, and Smith SM.** Temporal autocorrelation in univariate linear modeling of FMRI data. *Neuroimage* 14: 1370–1386, 2001.
- Worsley KJ, Evans AC, Marrett S, and Neelin P.** A three-dimensional statistical analysis for CBF activation studies in human brain. *J Cereb Blood Flow Metab* 12: 900–918, 1992.